

# *Sister Mary Joseph's Nodule as a Presenting Sign of Recurrent Gastric Carcinoma: A Case Report and Literature Review*

**Chakrapan Euanorasetr, MD**

*Department of Surgery, Faculty of Medicine, Ramathibodi Hospital, Mahidol University, Bangkok, Thailand*

---

**Abstract**

Sister Mary Joseph's nodule (SMJN) is an uncommon manifestation of advanced gastric carcinoma, but it is a very important and interesting clinical sign with rich history. The presence of SMJN often indicates advanced intra-abdominal/pelvic malignancies. The ease of identifying this nodule emphasizes the importance of thorough and careful examination of the umbilicus. We herein report a case of patient presenting with SMJN as the first sign of recurrent gastric carcinoma. She received palliative surgical resection of the recurrent tumors. This case is reported in order to emphasize the need for thorough examination of any umbilical lesion in patient with advanced gastric carcinoma.

**Keywords:** gastric carcinoma, Sister Mary Joseph's nodule, umbilicus

---

## INTRODUCTION

A metastatic lesion of the umbilicus associated with intra-abdominal malignancy is known as Sister Mary Joseph's nodule (SMJN). It is well known but uncommon phenomenon and represents only 10% of all cutaneous metastasis<sup>1-3</sup>. SMJN is encountered in 1-3% of patients with intra-abdominal or pelvic malignancies<sup>4-7</sup>. It usually manifests as an umbilical nodule with irregular margins and hard fibrous consistency<sup>8</sup>. It may also present as uncharacteristic diffuse hardening of the umbilical region<sup>9</sup>. The skin covering the nodule is usually of normal color but may be red or purple and progresses to a malignant ulcer<sup>10</sup>. It is often painless unless the overlying skin is ulcerated<sup>6,11</sup>. The size of the nodule usually ranges from 0.5 to 2 cm, although some nodules may reach up to 10 cm in size<sup>5,8,12</sup>.

The available information of SMJN is scarce and consists of case reports. In 1966, Barrow reported 202 cases of SMJN between 1916 and 1966<sup>13</sup>. Until 2007, the SMJN has been reported in more than 400 cases in the world literatures<sup>9</sup>.

## CASE REPORT

A 35-year-old woman presented with a painless umbilical nodule for one month. She was a known case of gastric carcinoma at the whole gastric antrum with peritoneal metastasis and transverse colon invasion. Subtotal gastrectomy with Billroth II anastomosis and transverse colectomy with end-to-end anastomosis was performed 11 months ago. The pathologic report of the stomach showed poorly differentiated adenocar-

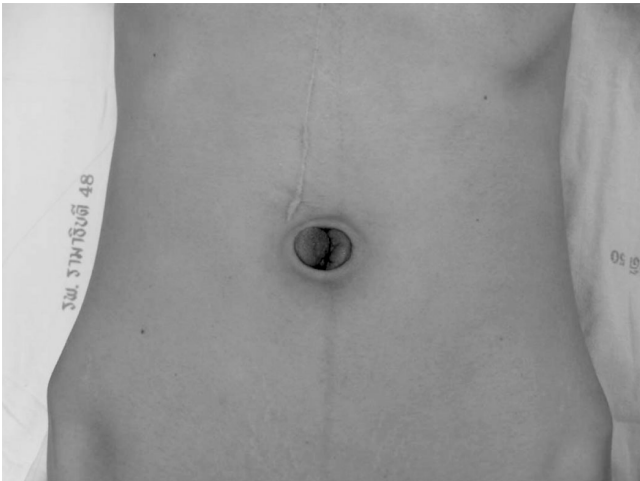
---

**Correspondence address:** Chakrapan Euanorasetr, MD, Department of Surgery, Faculty of Medicine, Ramathibodi Hospital, Mahidol University, Bangkok 10400, Thailand; Telephone: +66 2201 1315; Fax: +66 2201 1316; Email: racen@mahidol.ac.th

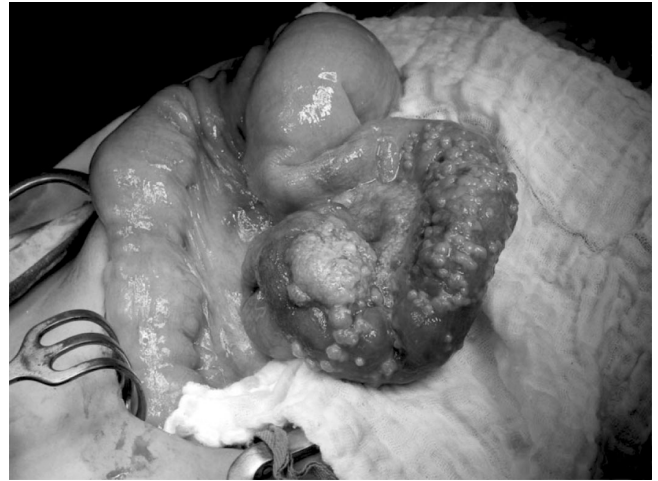cinoma. Transverse colon and omentum also showed poorly differentiated adenocarcinoma. Lymph nodes were positive in 5 out of 23 nodes. She received postoperative oral chemotherapy with tegafur and uracil. Eleven months after surgery, she presented with an umbilical nodule. Physical examination revealed firm to hard consistency and painless umbilical nodule, measuring 2-3 cm in diameter (Figure 1, 2). There was no other abdominal mass and no sign of ascites. SMJN was suspected due to recurrent gastric carcinoma. CT scan of the abdomen and pelvis was requested to investigate other intra-abdominal recurrence. During this waiting period, she developed intermittent abdominal pain and distension with anorexia and weight loss. The diagnosis was partial small bowel obstruction. The CT scan demonstrated

long segment of metastatic tumor at the jejunum, causing partial obstruction, multiple peritoneal metastases at cul-de-sac, and an enhancing soft tissue mass at umbilicus, measuring  $2.6 \times 3.2$  cm in size. The CT finding supported the diagnosis of SMJN.

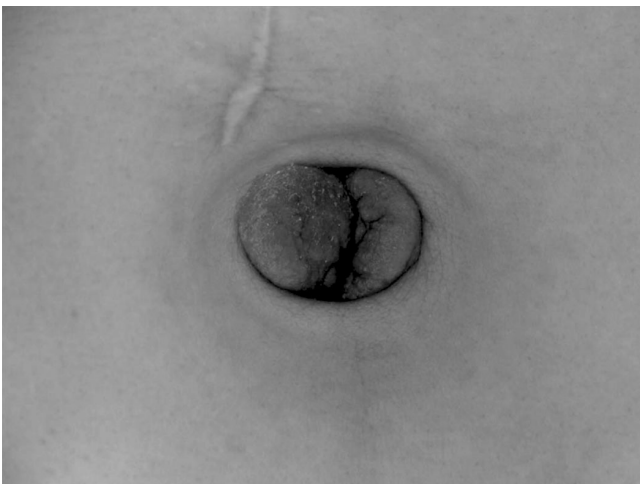
The patient underwent exploratory laparotomy with the indication of small bowel obstruction. Operative finding showed carcinomatosis peritonei, hard umbilical mass and two large tumor masses at the jejunum and ileum with partial obstruction of the lumen (Figure 3). Segmental resection of the jejunal and ileal segments with end-to-end anastomosis and resection of the umbilicus was performed (Figure 4, 5). The pathologic report of the jejunal and ileal segment showed poorly differentiated adenocarcinoma, signet ring cell tumor and presence of lymphovascular



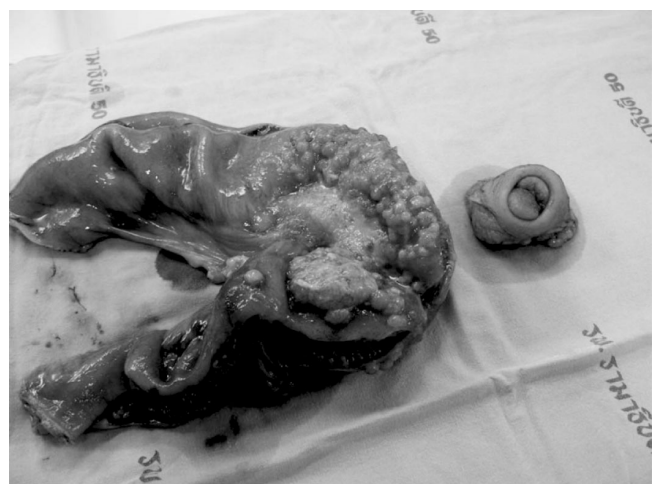**Figure 1** Sister Mary Joseph's nodule



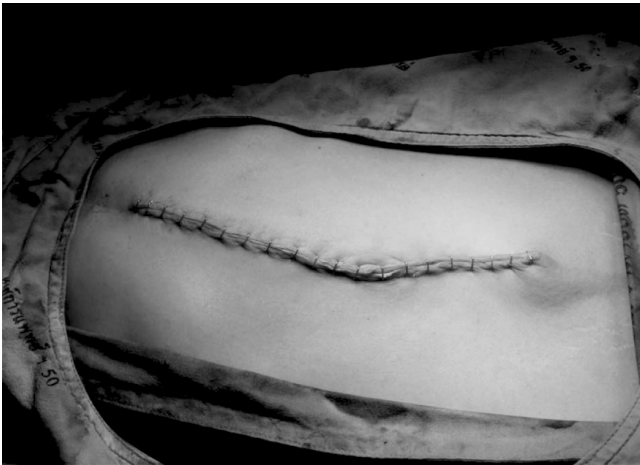**Figure 3** Tumor mass at ileum with partial obstruction



**Figure 2** Sister Mary Joseph's nodule



**Figure 4** Specimens of jejunal segment and umbilicus



**Figure 5** Laparotomy wound

invasion. Pathologic report of the umbilicus also revealed metastatic poorly differentiated adenocarcinoma, involving full thickness of skin and peritoneum, presence of lymphovascular invasion and free all surgical margins.

### DISCUSSION

SMJN is named after Sister Mary Joseph (1853-1939), a superintendent nurse at St. Mary's Hospital (one of the two major hospitals of Mayo Clinic, Rochester, USA). She is also the first surgical assistant to Dr. William James Mayo in the early days of Mayo Clinic. She had many responsibilities including skin preparation for patients scheduled for abdominal surgery. She observed that some patients with gastric carcinoma had firm mass at their umbilicus. She also noticed that this umbilical nodule was associated with advanced cancer and patient had generally poorer outcome and died of their cancer earlier than those who did not have umbilical mass<sup>11,14,15</sup>. She drew Dr. Mayo's attention to this sign. Dr. William James Mayo reported this condition as "pants-button" umbilicus (without credit to Sister Mary Joseph) in a lecture to the Cincinnati Academy of Medicine in 1928<sup>15</sup>. The term SMJN did not exist until 10 years after her death. In 1949, Sir Hamilton Bailey proposed that this umbilical nodule should be called "Sister Mary Joseph's nodule" in the 11<sup>th</sup> edition of his famous textbook "Physical Signs in Clinical Surgery", in honor of Sister Mary Joseph<sup>16</sup>. The original surgical building at St. Mary's Hospital, Mayo Clinic is now named "Joseph Building" in her memory.

The mode of spread by which a gastric carcinoma can metastasize to the umbilicus has been postulated to occur in several ways. Contiguous extension of metastasis from the peritoneal surface is thought to be the most important route<sup>5,8-10</sup>. The umbilicus is a scar which is connected to multiple embryologic remnants. Direct extension along the ligaments of embryonic origin is another possible route of metastatic spread<sup>5,8-10</sup>. Metastatic tumors of the umbilicus, constitute 83% of all malignant umbilical tumors and are much more common than primary malignant tumor of the umbilicus<sup>5,7</sup>. The vast majority (70%-90%) of the SMJN were metastatic adenocarcinoma<sup>5,17</sup>. In men, the GI tract, especially the stomach is the most common location of the primary malignancy, whereas in woman, gynecologic malignancy, particularly ovarian cancer is the most common<sup>1,5,11,18-23</sup>. Other possible primary sites include colonic cancer<sup>24,25</sup>, pancreatic cancer<sup>9</sup>, gastric lymphoma<sup>26</sup>, gall bladder cancer<sup>27</sup>, hepatocellular carcinoma<sup>28,29</sup>, prostatic cancer<sup>20,30,31</sup>, endometrial cancer<sup>32</sup>, cervical cancer<sup>33</sup> and squamous cell carcinoma of the esophagus<sup>34</sup>. SMJN is predominated in female. This is probably due to a large number of gynecologic malignancies in women that might involve the umbilicus in addition to the GI tract malignancies in both genders<sup>35</sup>. An umbilical lesion can be either benign or malignant<sup>36</sup>. Potential benign lesions include umbilical hernia, umbilical endometriosis externa (Villar's nodule), foreign body granuloma, dermatofibroma, urachal cyst<sup>36,37</sup>. A malignant umbilical mass can represent a primary or metastatic lesion. Primary umbilical carcinoma include melanoma, squamous cell carcinoma, basal cell carcinoma and adenocarcinoma<sup>38-40</sup>. Primary umbilical adenocarcinomas are extremely rare<sup>39</sup>. The two umbilical remnants from which primary umbilical adenocarcinoma can arise are the vittello-intestinal (omphalo mesenteric) tract and the urachus<sup>39,40</sup>. The diagnosis of primary umbilical adenocarcinoma can be suspected when an alternative primary cancer has been searched for but not found<sup>39</sup>. Since many conditions can mimic this umbilical metastasis, histological confirmation is always requisite before labeling this finding as SMJN. The primary tumor site is usually detected because most umbilical metastasis have specific morphologies and immunohistochemical features that enable a prediction of the primary tumor<sup>38</sup>. At least two series reported eleven cases of SMJN diag-

nosed by fine needle aspiration cytology (FNAC)<sup>41,42</sup>. They suggested FNAC as an initial diagnostic procedure in case suspected SMJN. However, the source of the primary tumor remained unknown in 11% to 30% of patients<sup>5,24,43</sup>.

SMJN can be the first and only presenting sign of an underlying intra-abdominal malignancy<sup>11</sup> and therefore should prompt a thorough search for the primary tumor, or as demonstrated in our case, a sign of disease progression or recurrence in a patient with a previous history of intra-abdominal malignancy<sup>5</sup>. Usually the presence of SMJN indicates a poor prognosis. The survival rate varies with the primary tumor but is usually less than 12 months, with less than 15% surviving more than 2 years<sup>4,44,45</sup>. The survival in most series range from 2 to 11 months from the time of initial diagnosis<sup>7,8,10,46</sup>. Since the prognosis is extremely poor, surgery is usually not indicated<sup>8,36</sup>, but the existence of SMJN is an insufficient proof of inoperable case<sup>1</sup>. In some patients, however, depending on the site of the primary neoplasm and the patient general conditions, surgery and/or chemotherapy may improve survival and quality of life<sup>4</sup>. A better survival rate is possible in patients with primary ovarian carcinoma<sup>47</sup> or if SMJN is a solitary metastasis<sup>5</sup>.

### CONCLUSIONS

The most important clinical clues for diagnosing an umbilical metastasis presenting with SMJN come from patient history and physical examination. A careful examination of the umbilicus is recommended in patient with gastric carcinoma. Whenever it is possible, an aggressive surgical approach combined with chemotherapy treatment should be considered to offer the patient the best survival probability.

### ACKNOWLEDGEMENT

The author thanks Mrs. Woraporn Sriyodwieng for her assistance in preparing the manuscript.

### REFERENCES

1. Al-Mashat F, Sibiany AM. Sister Mary Joseph's nodule of the umbilicus: is it always of gastric origin? A review of eight cases at different sites of origin. *Indian J Cancer* 2010;47:65-9.
2. Lookingbill D, Spangler N, Sexton FM. Skin involvement as the presenting sign of internal carcinoma. A retrospective study of 7316 cancer patients. *J Am Acad Dermatol* 1990;22:19-26.
3. Nakamura M, Tamura J, Takaki R, et al. Sister Mary Joseph's nodule. *Intern Med* 2009;48:1775.
4. Khan AJ, Cook B. Metastatic carcinoma of umbilicus: "Sister Mary Joseph's nodule". *Cutis* 1997;60:297-8.
5. Dubreuil A, Domp Martin A, Barjot P, et al. Umbilical metastasis or Sister Mary Joseph's nodule. *Int J Dermatol* 1998;37:7-13.
6. Zadeh VB, Kadyan R, Al-Abdulrazzaq A, et al. Sister Mary Joseph's nodule: a case of umbilical cutaneous metastasis with signet ring cell histology. *Indian J Dermatol Venereol Leprol* 2009;75:503-5.
7. Shen Z, Yang X, Chen L, et al. Sister Mary Joseph's nodule as a diagnostic clue to metastatic colon carcinoma. *J Clin Oncol* 2009;27:e1-2.
8. Gabriele R, Conte M, Egidi F, et al. Umbilical metastases: current viewpoint. *World J Surg Oncol* 2005;3:13.
9. Yendluri V, Centeno B, Springett G. Pancreatic cancer presenting as a Sister Mary Joseph's nodule: case report and update of the literature. *Pancreas* 2007;34:161-4.
10. Lin CC, Liu KL, Lin JT, et al. Education and imaging. Gastrointestinal: Sister Mary Joseph nodule. *J Gastroenterol Hepatol* 2008;23:1462.
11. Abu-Hilal M, Newman JS. Sister Mary Joseph and her nodule: historical and clinical perspective. *Am J Med Sci* 2009;337:271-3.
12. Piura B. Umbilical metastasis: Sister Mary Joseph's nodule. *Harefuah* 2006;145:505-9.
13. Barrow MV. Metastatic tumors of the umbilicus. *J Chronic Dis.* 1966;19:1113-7.
14. Steensma DP. Sister (Mary) Joseph's nodule. *Ann Intern Med* 2000;133:237.
15. Albano EA, Kanter J. Sister Mary Joseph's nodule. *N Engl J Med* 2005;352:1913.
16. Bailey H. Demonstration of physical signs in clinical surgery, 11th ed. Baltimore: Williams & Wilkins; 1949. p. 227.
17. Powell FC, Cooper AJ, Massa MC, et al. Sister Joseph's nodule: a clinical and histologic study. *J Am Acad Derm* 1984;10:610-5.
18. Lee CK, Chang YW, Jung SH, et al. A case of Sister Mary Joseph's nodule as a presenting sign of gastric cancer. *Korean J Gastroenterol* 2008;51:132-6.
19. Whang TB, Wang L, Peng DH. Gastric carcinoma of the umbilicus: case report of Sister Mary Joseph nodule. *Cutis* 2010;85:90-2.
20. Sina B, Deng A. Umbilical metastasis from prostate carcinoma (Sister Mary Joseph's nodule): a case report and review of literature. *J Cutan Pathol* 2007;34:581-3.
21. Limmathurotsakul D, Rerknimitr P, Korkij W, et al. Metastatic mucinous cystic adenocarcinoma of the pancreas presenting as Sister Mary Joseph's nodule. *JOP* 2007;8:344-9.
22. Baratta A, Gorin RJ, Costa R. Sister Mary Joseph nodule: a case report. *Cutis* 2007;80:469-72.

23. Clague JE. Sister Joseph's nodule. *Postgrad Med J* 2002; 78:174.
24. Gabriele R, Borghese M, Conte M, et al. Sister Mary Joseph's nodule as a first sign of cancer of the cecum: report of a case. *Dis Colon Rectum* 2004;47:115-7.
25. Wu YY, Xing CG, Jiang JX, et al. Carcinoma of the right side colon accompanied by Sister Mary Joseph's nodule and inguinal nodal metastases: a case report and literature review. *Chin J Cancer* 2010;29:239-41.
26. Hopton BP, Wyatt JI, Ambrose NS. A case of Sister Mary Joseph nodule associated with primary gastric lymphoma. *Ann R Coll Surg Engl* 2005;87:W6-7.
27. Renner R, Sticherling M. Sister Mary Joseph's nodule as a metastasis of gallbladder carcinoma. *Int J Dermatol* 2007; 46:505-7.
28. Hodgkinson HJ, Kew MC. Sister Joseph's nodule in hepatocellular carcinoma. *Eur J Gastroenterol Hepatol* 2001;13:865-7.
29. Liu CY, Yong CC, Wu SC, et al. Sister Mary Joseph's nodule associated with hepatocellular carcinoma. *Surgery* 2010; 147:167-8.
30. Fukuda H, Saito R. A case of Sister Mary Joseph's nodule from prostatic cancer. *J Dermatol* 2006;33:46-51.
31. Deb P, Rai RS, Rai R, et al. Sister Mary Joseph nodule as the presenting sign of disseminated prostate carcinoma. *J Cancer Res Ther* 2009;5:127-9.
32. Piura B, Meirovitz M, Bayme M, et al. Sister Mary Joseph's nodule originating from endometrial carcinoma incidentally detected during surgery for an umbilical hernia: a case report. *Arch Gynecol Obstet* 2006;274:385-8.
33. Behtash N, Mehrdad N, Shamshirsaz A, et al. Umbilical metastasis in cervical cancer. *Arch Gynecol Obstet* 2008; 278:489-91.
34. Wijekoon NS, Samarasekera DN. Sister Mary Joseph's nodule as the sole presenting feature of disseminated squamous cell cancer of the esophagus: a rare case. *J Gastrointest Cancer* 2007;38:99-101.
35. Touraud JP, Lentz N, Dutronc Y, et al. Umbilical cutaneous metastasis (or Sister Mary Joseph's nodule) disclosing an ovarian adenocarcinoma. *Gynecol Obstet Fertil* 2000;28: 719-21.
36. Lee WJ, Chou CJ. Sister Mary Joseph's nodule. *Emerg Med J* 2006;23:956.
37. Victory R, Diamond MP, Johns DA. Villar's nodule: a case report and systematic literature review of endometriosis externa of the umbilicus. *J Minim Invasive Gynecol* 2007; 14:23-32.
38. Kolwijck E, Kruitwagen RF, Massuger LF. Sister Mary Joseph nodule as a first and only sign of extraovarian carcinoma: a case report and review of the literature. *Arch Pathol Lab Med* 2008;132:1943-5.
39. Alnaqbi KA, Joshi S, Ghazal-Aswad S, et al. Primary umbilical adenocarcinoma. *Singapore Med J* 2007;48:e308-10.
40. Meine JG, Bailin PL. Primary melanoma of the umbilicus: report of a case and review of the relevant anatomy. *Dermatol Surg* 2003;29:405-7.
41. Handa U, Garg S, Mohan H. Fine-needle aspiration cytology of Sister Mary Joseph's (paraumbilical) nodules. *Diagn Cytopathol* 2008;36:348-50.
42. Gupta RK, Naran S, McHutchison AG, et al. Diagnosis of umbilical metastasis (Sister Mary Joseph's nodule) by fine-needle aspiration: an immunocytochemical study. *Diagn Cytopathol* 1994;10:126-9.
43. Galvañ VG. Sister Mary Joseph's nodule. *Ann Intern Med* 1998;128:410.
44. Larentzakis A, Theodorou D, Fili K, et al. Sister Mary Joseph's nodule: Three case reports. *Cases J* 2008;1:182.
45. Sugarbaker PH. Sister Mary Joseph's sign. *J Am Coll Surg* 2001;193:339-40.
46. Masmoudi A, Boudaya S, Charfeddine A, et al. Sister Mary Joseph's nodule: report of five cases. *Int J Dermatol* 2008; 47:134-6.
47. Majmudar B, Wiskind AK, Croft BN, et al. The Sister (Mary) Joseph nodule: its significance in gynaecology. *Gynecol Oncol* 1991;40:152-9.